

# The Equine Upper Airway

*Understanding the structure and function of the equine upper respiratory system are key to knowing what can go wrong with a horse's breathing*

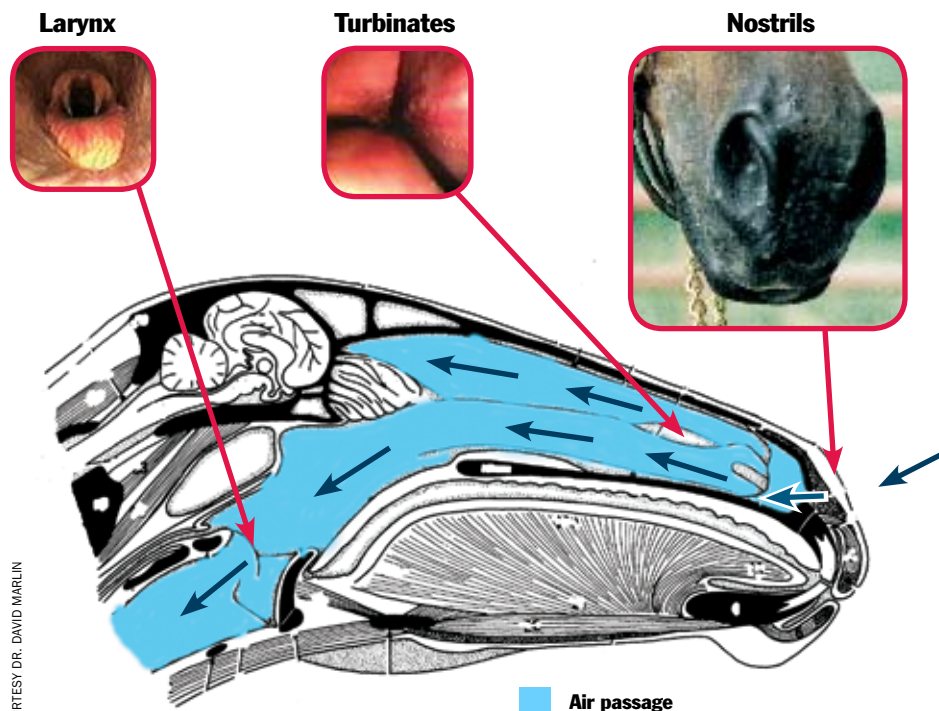
## Overview

The upper respiratory tract is the portion of the respiratory system extending from the nares (the external portion of the nose, also called the nostrils) to the larynx, which is the cartilaginous structure located at the top of the trachea. Since respiratory dysfunction is a major cause of poor performance in athletic horses (second only to musculoskeletal disorders), a basic knowledge of the structure and function of the respiratory system, particularly the upper respiratory tract, is important for horse owners.

## Structure of the Upper Airway

In its simplest form, the upper respiratory tract can be considered a hollow, muscular tube beginning at the nose and extending to the back of the throat, the nasopharynx, where the trachea commences. The nasal passage consists of paired nasal cavities (separated by the nasal septum) and paired paranasal sinuses. These sinuses are air-filled cavities in the bones of the skull. The nasal septum is continuous with the upper surface of the hard palate, which separates the nasal and oral cavities. The hard palate becomes the soft palate, which divides the nasopharynx from the oropharynx (mouth). The term pharynx refers to the anatomic region of the respiratory and gastrointestinal systems that extends from the nasal and oral cavities to the top of the trachea. In the horse, the soft palate is very long, extending from the hard palate to the base of the epiglottis and making the horses an obligate nasal breather. Specifically, the epiglottis rests on top of the soft palate, which effectively prevents air from flowing through the mouth and oropharynx to the trachea and lungs.

The epiglottis is a movable, cartilaginous structure that is part of the larynx (commonly referred to as the voice box). The



The horse does not breathe through its mouth and nose like we do. The horse only breathes through its nostrils. The nasal passages in the horse are separated from the oral (mouth) cavity. Horses only breathe through their mouths if they have an injury or abnormality to the soft palate (the structure that separates the mouth from the nasal passages).

larynx is also comprised of the cricoid, thyroid, and paired arytenoid cartilages. Other important larynx structures include the aryepiglottic folds, the vocal cords, and the glottic cleft (the entrance to the larynx).

The guttural pouches are unique to members of the equidae family. They are located on either side of the base of the skull. Technically they are diverticulae (outpouchings) of the auditory tube with a volume of up to a half-liter.

The tongue, located in the oropharynx and oral cavity, while commonly considered part of the gastrointestinal system, actually plays an important role in the upper respiratory system (described below).

Other important structures of the upper airway include a plethora of muscles, membranes, cranial and peripheral nerves, blood vessels, salivary glands and ducts, connective tissues, and lymphatic tissues that all function together to maintain patency of the upper airway.

## Function of the Upper Airway

There are three primary functions of the upper respiratory tract: breathing, swallowing, and vocalization. In performance horses, the breathing process is primarily of interest because malfunctions can cause a horse to perform badly. .

Air enters the upper respiratory tract

via the nares and passes through the nasal cavities, where it is warmed and filtered. The air continues into the nasopharynx, over the epiglottis, and through the larynx into the trachea. The muscles of the nasopharynx are paramount in maintaining a patent airway, as are the soft palate and all of the structures of the larynx. Surprisingly, the tongue plays an important role in the respiratory system as it ensures correct positioning of the larynx.

When horses exercise, pulmonary resistance approximately doubles, with 50% of the total resistance originating within the narrow nasal passages.

### When Things Go Wrong

Considering the complex anatomy of the upper respiratory tract and the tremendous airflow and pressure fluctuations that occur within the upper respiratory tract during exercise, it is not surprising that upper airway dysfunction is so common. Some of the most commonly diagnosed upper airway abnormalities include:

**Dorsal displacement of the soft palate (DDSP)** This occurs when the free end of the soft palate is located above the epiglottis

(instead of lying underneath the epiglottis), effectively blocking the flow of air through the nasopharynx to the larynx and trachea.

**Nasopharyngeal collapse** This is the movement or collapse of any or all of the “walls” of the nasopharynx that causes disruption of the flow of air from the nasal cavities to the larynx and trachea.

**Laryngeal hemiplegia (roaring)** Defined as paralysis of the nerve innervating the larynx (usually the left side of the larynx) that results in drooping of the arytenoid cartilage and vocal fold into the larynx, thereby impeding airflow through the larynx to the trachea.

**Epiglottic entrapment** This condition occurs when the apex and lateral margins of the epiglottis are completely enveloped within the arytenoepiglottic fold. While the epiglottis remains dorsal to the soft palate as normal, its function is (usually) inhibited when entrapped.

Performance problems and respiratory noise are common in horses affected with these conditions. Diagnosis, treatment, and prognosis will vary depending on the exact underlying cause. 🐾

## FAST FACTS

- **The upper respiratory tract** is the portion of the respiratory system extending from the nares to the larynx.
- **Key anatomic structures** include the nasal cavities, paranasal sinuses, nasopharynx, soft palate, tongue, and larynx.
- **The three primary functions** of the upper respiratory tract are breathing, swallowing, and vocalization.
- **During breathing**, air enters the nasal cavities via the nares, passes through the nasopharynx and larynx, and enters the lower airway via the trachea.
- **Upper respiratory dysfunction** is common in horses.
- Any condition impeding the flow of air from the nares to the trachea can result in respiratory noise and exercise intolerance.
- **Problems** include DDSP, nasopharyngeal collapse, laryngeal hemiplegia, and epiglottic entrapment.